

Delayed Primary Closure of Diabetic Foot Wounds using the DermaClose™ RC Tissue Expander

David L. Nielson, DPM¹✉, Stephanie C. Wu, DPM, MSc²✉, David G. Armstrong, DPM, PhD³✉

The Foot & Ankle Journal 1 (2): 3

Closure of large wounds has been a challenge in podiatric surgery, especially after large defects created by ulcer debridement, metatarsal resection and amputation. The DermaClose™ RC tissue expander allows for closure of large defects without the need for traditional complex skin closure, tissue grafting or creation of skin and tissue flaps. Skin anchors made of surgical steel clips are used with a tension controller to allow for gentle skin stretching on the subcutaneous planes of the wound or defect. It also has special application in the closure of chronic wounds. Two case reports are presented to describe this technique.

Mechanically assisted delayed primary closure of large foot wounds following emergency or ablative surgery will result in faster healing and assist in enhanced closure of a large tissue defect. The technique of rapid wound closure is enhanced with the use of the DermaClose™ RC tissue expanding device. The application of the device is simple and provides for a less complex treatment course than secondary wound closure.

Tissue expansion was first employed by placing straight wires (0.045-0.062) through the skin adjacent to the wound. Special ratcheting devices, suture, or 28 gauge wire are used to bring the straight wires closer thus exploiting stress relaxation inherent in skin.¹⁻⁴ A variety of companies make several devices to accomplish the same goal today.

Mechanically assisted wounds have been shown to close up to 40% quicker than traditional secondary intention healing.¹

When a wound is created, healing is either by primary closure if enough tissue is available or by secondary intention healing. Many times, in podiatry, large wounds and defects are created after ulcer debridement, metatarsal or bone resection and amputation. Secondary intention wound healing can be facilitated by a variety of modalities including local wound care, negative pressure vacuum therapy, hyperbaric therapy, tissue growth factors and application of bioengineered tissue equivalents. However, secondary intention healing of the defect often take weeks or months adding to the cost of wound and palliative care.

Delayed primary closure can also be challenging, especially in the foot. Many times this will include complex tissue closure, tissue grafts and adjacent tissue flaps to promote full wound closure.

The tissue expansion device now allows for rapid closure. It can also provide cost savings in respect to decreasing the need for prolonged wound care. We present two case reports describing the use of the DermaClose™ tissue expanding device.

^{1,2,3} Scholl's Center for Lower Extremity Ambulatory Research (CLEAR) at Rosalind Franklin University of Medicine and Science.

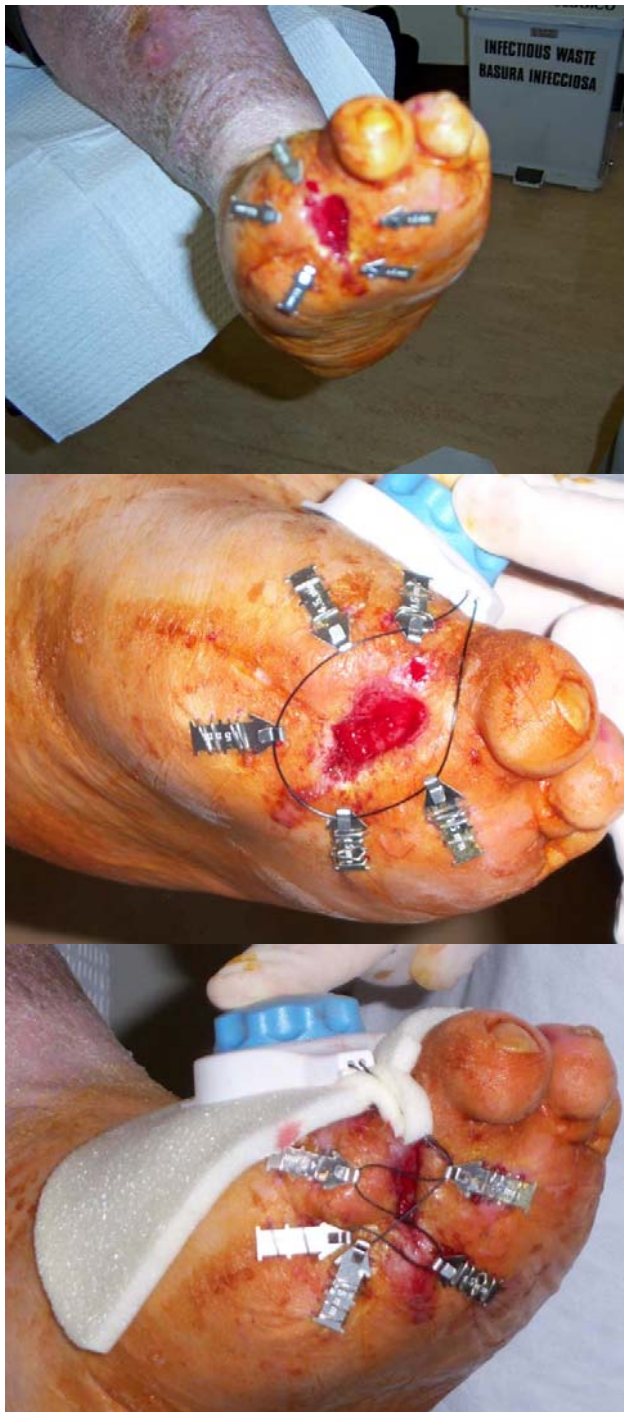


Figure 1 Case #1 shows the patient post amputation with local dehiscence of the wound edges. Here, the DermaClose™ Clips are placed around the wound and the wound edges are approximated under tension. The suture is applied in a circular or figure-8 fashion. It is important to also protect the foot with foam from the overlying tension device.

Case #1

A 59 year old Caucasian male presents to our clinic with a chronic 3 year wound after a hallux and 2nd digital amputation. The patient has a long history of diabetes mellitus and has undergone kidney transplantation.

Application of the DermaClose™ device was initiated and it required about 3 months to close completely. The patient was taking immunosuppressive medication during this time, which may explain the prolonged closure rate.

The surgical site is thoroughly cleansed before application of the tissue anchors. A suture loop is then placed through the anchors and tension is applied by the device. In this case, a figure-8 suture was used to apply uniform tension perpendicular to the skin edges. (Fig.1)

Case #2

A 42 year old African-American male presents to our clinic after stepping on a bottle cap in March 2007. The patient is a poorly controlled diabetic with serum glucose running between 250 and 350 mg/dL. His medications include oral hypoglycemics, injectable Insulin and cholesterol lowering drugs. Unfortunately, he developed infection and underwent incision and drainage of deep space abscess with second partial metatarsal resection and digital amputation.

Prior to delayed closure and use of the DermaClose™ device, the patient underwent a series of wound care treatments, negative pressure wound VAC and application of Graft Jacket. After several months, the amputation site failed to close and a large, granulating defect remained. (Fig. 2)

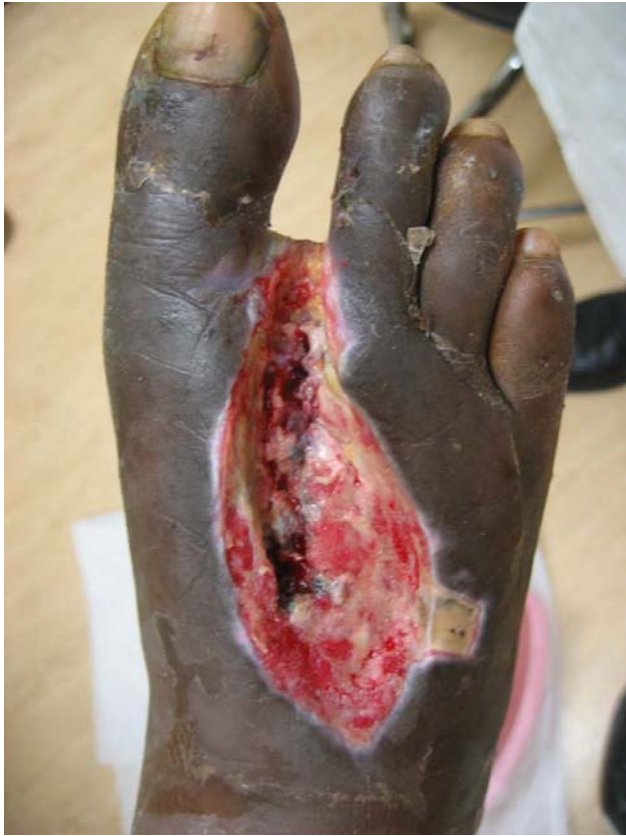

Figure 2 Case #2 represents a large, chronic post-amputation defect.

In order to promote final closure, the DermaClose™ tissue expanding device was applied. Preparation of the wound consists of surgical debridement of all non-viable tissue. The wound edges are undermined about 2cm from the wound edge. (Fig. 3) During the tension phase, the patient remained in a CAM boot and underwent daily dressing changes. Final closure of the defect was accomplished within just a few days of application. (Fig. 4,5)

Application

The device describe, (DermaClose™, Wound Care Technologies, Chanhassen, MN, USA) consist of skin anchors made of 316L surgical stainless steel and placed circumferential to the wound 1-1.5 cm from the wound edge.

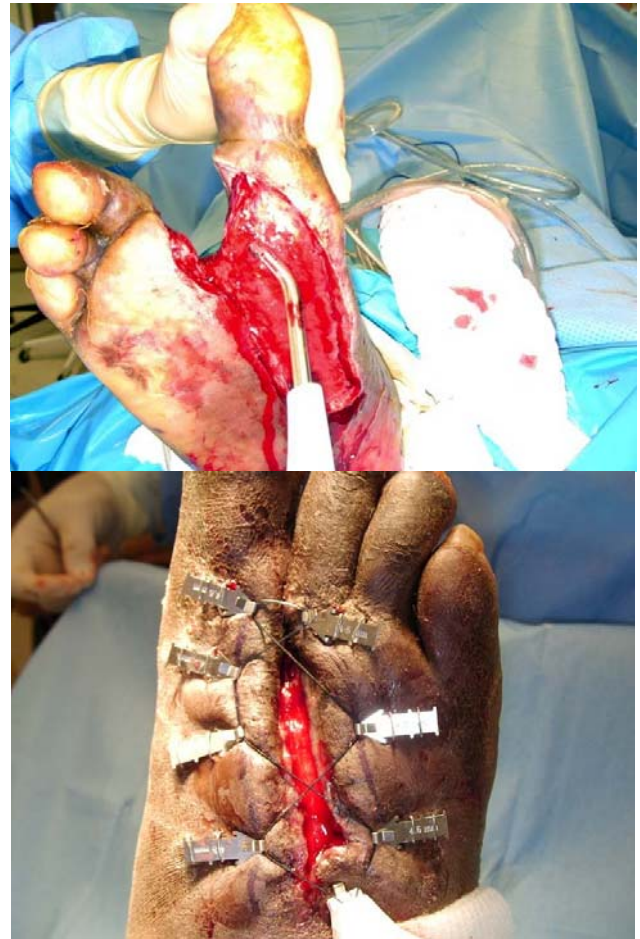

Figure 3 The wound must be surgically debrided of all non-viable tissue prior to application of the device. The device is applied and within 3 days the dorsal defect closed. Here, the anchors are tensioned in a shoe-lace fashion.

The anchors penetrate the skin and into the subcutaneous tissue. Each anchor is held in place with two skin staples. A monofilament, high strength suture is then woven around each anchor.

The suture is then tightened to approximately 1.3kg of force, bringing the wound edges closer together. Once the dynamic tension is reached, additional tightening is not needed.

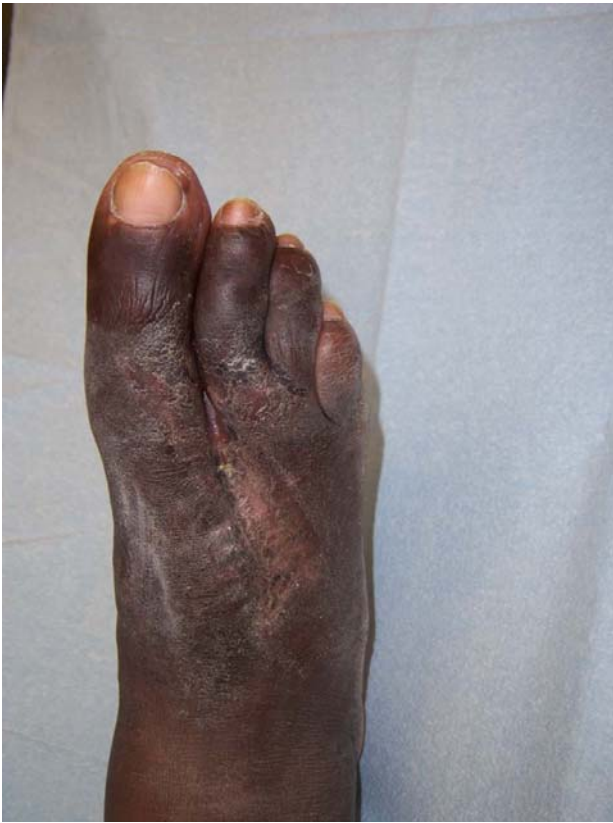

Figure 4 Closure of the chronic wound using the DermaClose™ device.

Patients should be seen every 3-5 days for evaluation of the device and the tissue movement. Care should be noted that the anchors do not envelop or imprint into the skin.

The DermaClose™ tension controller is attached around each skin anchor and the knob of the tension device is rotated until a clutch mechanism provides an audible indication that full tension has been achieved. The device now maintains the proper amount of tension to gently stretch the skin on the subcutaneous planes around the wound until the edges of the wound are brought close enough together for final suturing and closure.

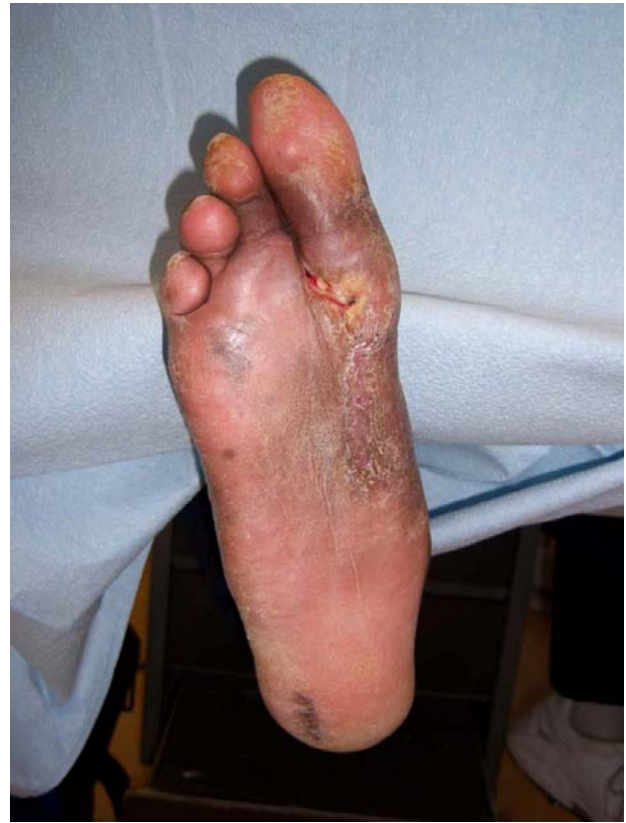

Figure 5 Plantar view of the closed wound. A separate DermaClose™ device was applied plantarily.

Discussion

In both cases, the wounds are considered chronic, diabetic wounds. The rate of closure varied in case #1 due to immunosuppressive therapy. In general, the DermaClose™ device will provide rapid closure of an otherwise chronic or stagnant wound.

In one of the first studies to evaluate rates of mechanically assisted closure, Armstrong and Lavery reported that closure can be assisted approximately 40% faster than by secondary intention healing alone.¹

Optimal results were obtained by strict off-loading of the foot during the tension phase of treatment, debridement with meticulous and frequent wound care. Armstrong and Lavery also identified the average healing time of a standard wound was similar to total contact casting.

Both cases represent a cross-sectional example of a small, chronic wound and a larger defect after amputation. Both responded favorably to mechanically induced delayed primary closure.

Conclusion

As one advances from the simple to the complex wound, the theoretical risk for complications increases. Therefore, specialist working in this area should always try to expand his or her armamentarium to assist in wound simplification and closure. Skin stretching devices are among some of these tools. At the Center for Lower Extremity Ambulatory Research (CLEAR), we are experiencing success in utilizing such devices to augment the closure of wounds. Members of CLEAR were amongst the first to evaluate this technique in the lower extremity more than a decade ago. We believe that the quality and breadth of these devices are improving. This can only benefit us as we move forward.

References

1. Armstrong DG, Lavery LA. Mechanically Assisted, Delayed Primary Closure of Diabetic Foot Wounds. *JAPMA*;88(10):483-488, 1998.
2. Armstrong DG, Sorensen JS, Bushman TB. Exploiting the viscoelastic properties of pedal skin with the sure-closure skin stretching device. *JFAS*;34(3):247-253, 1995.
3. Armstrong DG, Wunderlich RP, Lavery LA. Reaching closure with skin stretching. Applications in the diabetic foot. *Clin Podiatr Med Surg*;15(1):109-116, 1998.
4. Hirshowitz B, Lindenbaum E, Har-Shai Y. A skin-stretching device for the harnessing of the viscoelastic properties of skin. *Plast Reconst Surg*;92:260-267, 1993.