

Subungual Benign Squamous Papilloma: A case report

by Al Kline, DPM¹✉

The Foot & Ankle Journal 2 (2): 3

Benign squamous verrucae is from HPV or human papillomavirus origin. It is commonly called verrucae vulgaris or common wart. Although not as common as plantar warts, a case is presented describing subungual squamous papilloma. Differential diagnosis and treatment is discussed.

Key words: Wart, subungual wart, papiloma virus, HPV, plantar warts

Accepted: January, 2009

Published: February, 2009

This is an Open Access article distributed under the terms of the Creative Commons Attribution License. It permits unrestricted use, distribution, and reproduction in any medium, provided the original work is properly cited. ©The Foot & Ankle Journal (www.faoj.org)

Verrucae or warts are problematic lesions to treat. Wart infection is the result of inoculation of human papilloma virus (HPV). The viral inclusion is commonly found in the nuclei of vacuolated cells present in the granular layer and stratum malpighii.¹ The virus will cause a benign epithelial hyperplasia giving the lesion a hard, hyperkeratinized appearance. Because of this appearance, the lesion is often called verrucae vulgaris. Usually, direct trauma that causes inoculation of the virus will initiate the localized viral infection. Warts are common to the hands, feet, elbows and other surfaces of the body. A less common area of infection is under the nail plate. The wart may start small and then begin to replicate creating a larger, hyperkeratotic growth. In our experience, patient's may wait an entire year before seeking medical attention.

The most common forms of wart treatment include local topical salicylic acid application, cryotherapy and laser cauterization. In subungual verrucae, topical treatments are difficult and may cause nail dystrophy, so excisional and surgical removal is usually indicated. The lesions can sometimes mimic in-situ squamous cell carcinoma or Bowen's disease² so excisional biopsy is recommended. Other differential diagnosis include basal cell carcinoma³, malignant melanoma⁴, subungual exostosis⁵, pyogenic granuloma, fibromas, epidermoid carcinomas and keratocanthomas.⁶

Case Presentation

A 6 year old girl presents to the office with a painful growth under the right hallux nail. (Fig.1) She is accompanied by her mother who noticed a small lesion that began to enlarge under the distal nail. Date of onset was 4 months prior to presentation.

Address correspondence to: Al Kline, DPM
3130 South Alameda, Corpus Christi, Texas 78404.

¹ Adjunct Clinical Faculty, Barry University School of Podiatric Medicine. Private practice, Chief of Podiatry, Doctors Regional Medical Center. Corpus Christi, Texas, 78411.

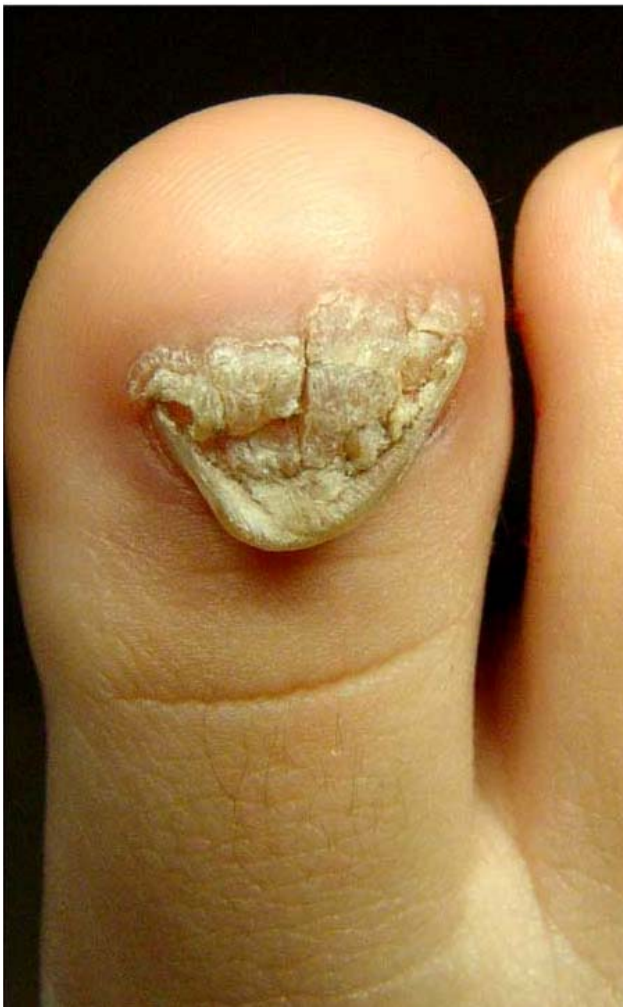

Figure 1 Initial presentation of subungual benign squamous papilloma of the right hallux.

Only recently did the growth become symptomatic. She cuts the nail back as the lesion grows. No previous treatment was initiated. Clinically, there is complete deformation of the nail plate. Fortunately, the matrix does not appear involved and the lesion appears to be growing along the distal one-third of the nail bed. It was decided the patient should undergo excision biopsy and removal of the lesion.

The patient underwent a local hallux block under intravenous sedation. A penrose drain tourniquet was applied for hemostasis. Under blunt dissection using a small hemostat, the nail was avulsed taking care not to injure the nail matrix. (Fig. 2)

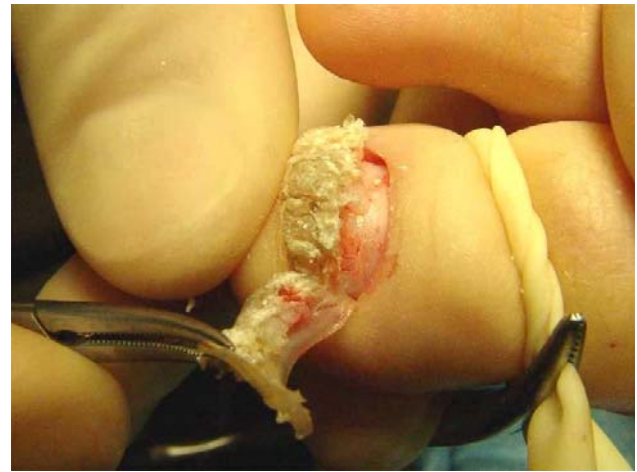

Figure 2 The nail plate is carefully removed from the nail matrix by blunt dissection. Fortunately, the papilloma did not invade the nail matrix.

Once the nail is removed, a number 15 blade is used to excise and curettage any remaining viral inclusions. Careful attention is maintained to curettage the lesion down through the reticular dermis to the superficial fascia. This layer is easily identifiable as a firm, fibrous region of tissue just under the epidermis. (Figs. 3 and 4) Any excision past this level may result in scarring. Adaptic® (Johnson & Johnson, Piscataway, NJ) and a simple Coban (3M, St. Paul, MN) dressing is placed on the toe after the procedure.

Pathology

The lesion was sent with both nail and verrucoid specimen in formalin. Microscopic sections show a squamous papilloma characterized by shallow surface papillomatosis, hypergranulosis and viral cytopathic effect as indicated by perinuclear halos marginating irregular nuclear membranes. Sections of the submitted toenail show characteristic microscopic features. Final diagnosis reads benign squamous papilloma with human papillomavirus cytopathic effect consistent with verruca plantaris.

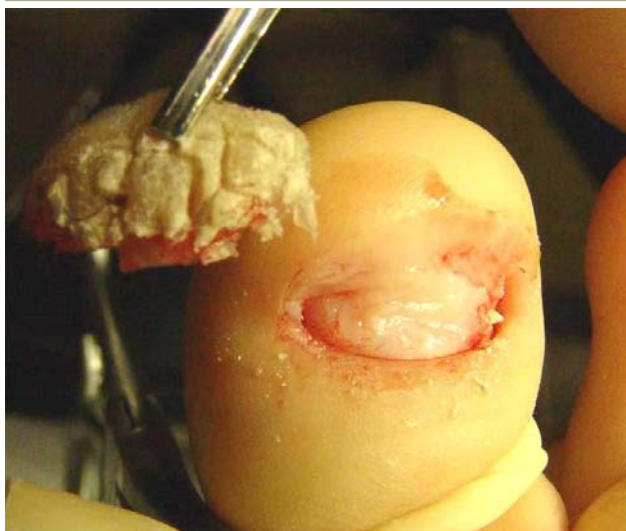


Figure 3 The papilloma is completely excised. Care is taken to excise the lesions down to the level of the reticular dermis and superficial fascia.

Discussion

Benign squamous papilloma or HPV is a common lesion involving the foot. Topical 40% salicylic acid in collodion suspension twice daily is the most common wart treatment regime that we use in our office. We also use the Trans Ver Sal® patch (Doak Dermatologics, Basking Ridge, NJ).⁷ However, the average length of wart resolution can range from 4 to 8 1/2 weeks.⁸ There is also a high recurrence rate following treatment of warts.

There are reports of up to 25 % failure rates with treatment of simple warts and 50% failure rates with mosaic warts.⁹ When symptomatic pain is a major complaint, surgical excision of the lesion is recommended. Careful attention to the level of excision is recommended in order to prevent scarring and decrease recurrence. Concerning pathology specimens submitted for laboratory analysis, Dr. Harvey Lamont, Director of the Laboratory of Podiatric Pathology in Philadelphia, PA. reported that *“clinicians often remove warts either too superficially or too deeply to the level of the subcutaneous fat.*

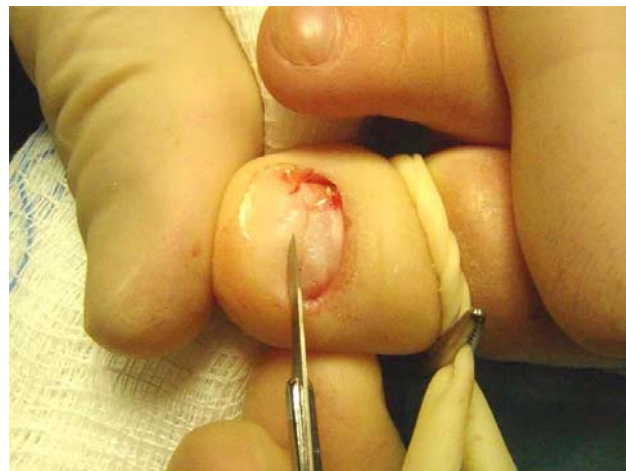

Figure 4 A number 15 blade is used to debride the superficial dense fascia from any viral inclusions.

*It has been our experience that when warts are removed from a level deeper than the skin, there is an increased potential for developing scar tissue.”*⁹ HPV's can produce a number of epithelial tumors of both the skin and mucous membranes. Over 100 HPV types have been detected with over 80 genomes already sequenced.¹⁰ Common warts are associated with HPV type 1,2,4,26,27,29,41,57 and 65. Plantar warts or *myrmecias* are associated with HPV type 1, 2, 4 and 63. In HPV infections, viral particles are released as a result of degeneration of desquamating cells. The HPV virus can also survive for many months at low temperatures without a host. Plantar warts can also spread virus by simply walking barefoot.¹⁰

The differential diagnosis for common warts, especially as they present subungually, can occasionally present as a malignant growth such as squamous cell carcinoma. In this case, prompt surgical excision and biopsy of any suspicious growth under the toenail is recommended.

References

1. LiVolsi, V. et al *Pathology 2nd Edition*, by John Wiley & Sons, Inc. 1989.
2. Kaiser JF, Proctor-Shipman L. Squamous cell carcinoma in situ (Bowen's disease) mimicking subungula verrucae vulgaris. *J Fam Pract.* 39 (4): 384 - 387, 1994.
3. Schrieber M. Nail Bed Carcinoma. *Cutis* 23: 597 - 599, 1979.
4. Mikhail GR Subungual Epidermoid Carcinoma. *J Am Acad Dermatol* 11: 291-298, 1984.
5. Woo TY, Rasmussen JE. Subungual Osteocartilaginous exostosis. *J Dermatol Surg Oncol.* 11 (5): 534 - 536, 1985.
6. Shapiro L, et al Subungual epidermoid carcinoma and keratoacanthoma *Cancer* 25: 141 - 152, 1970.
7. Doak Dermatologics Trans Ver Sal Patch, [online](#). Accessed 10/12/2006.
8. Young S, Cohen GE. Treatment of Verruca Plantaris with a Combination of Topical Fluorouracil and Salicylic Acid *JAPMA* 95(4): 366 - 369, 2005.
9. Lamont, H. Exploring Current Approaches to Plantar Warts. *Podiatry Today*, [online article](#), Accessed 10/12/2006.
10. Gearhart, Gearhart PA, Randall TC, Buckley RM. Human Papillomavirus. [eMedicine](#), Accessed 10/12/2006.