

# Intraepidermal Eccrine Adenocarcinoma of the Foot: A case report

by Natalie G. Cunningham, DPM<sup>1</sup>, Robert S. Crockett, DPM<sup>2</sup>, Donald Kushner, DPM<sup>3</sup>

The Foot and Ankle Online Journal 2 (7): 1

*Intraepidermal Eccrine Adenocarcinomas (IEA) are rare malignant tumors derived from the eccrine sweat glands of the skin. IEA occur equally in adult males and females between 50-80 years of age. Race is not a factor in prevalence of IEA. The incidence on the sole of the foot is unknown. The majority of IEA are associated with local aggressive metastasis. Therefore, Mohs microsurgery is now recommended, due to higher frequency of recurrence with surgical excision. Long term observation is indicated to ensure eradication of lesions, and for observation and treatment of any recurrence or metastases.*

**Key Words:** Intraepidermal, eccrine, adenocarcinomas, eccrine porocarcinomas, sweat duct, Mohs, foot ulcer.

Accepted: June, 2009

Published: July, 2009

This is an Open Access article distributed under the terms of the Creative Commons Attribution License. It permits unrestricted use, distribution, and reproduction in any medium, provided the original work is properly cited. ©The Foot and Ankle Online Journal ([www.faoj.org](http://www.faoj.org))

In 1956 Pinkus, et al., were the first to describe tumors exhibiting features of the epidermal sweat duct.<sup>4</sup> Evidence concerning the intraepidermal portion of the eccrine duct was initially presented in 1939 by Pinkus.<sup>4</sup> Intraepidermal Eccrine Adenocarcinoma (IEA) is classified with several other lesions that share similar pathological form, including: eccrine acrospiroma, eccrine porocarcinoma, malignant eccrine poroma and malignant hidroacanthoma simplex, among others. They vary in size from 1 – 10cm, averaging 2.5cm in most pedal cases.<sup>2</sup> Usually arising in skin of the head, neck and upper extremity, the majority of lower extremity lesions are found on the soles of the foot.<sup>6</sup> However, it is rare that these lesions are primary foot lesions.<sup>2</sup>

A benign form of IEA is eccrine acrospiroma, which can transform to a malignant form, especially in inveterate lesions.<sup>1</sup> The lesions of IEA can take on various morphology most often appearing as a single nodule or plaque, resembling plantar wart, ulcerated polypoid mass, or eroded plaque.<sup>3,6</sup> Biopsy is standard for diagnosing IEA. When IEA were first diagnosed it was thought that wide surgical excision was the treatment of choice, but recurrence rates were high. Now, Mohs microsurgery has become the standard treatment for IEA.

## Case Report

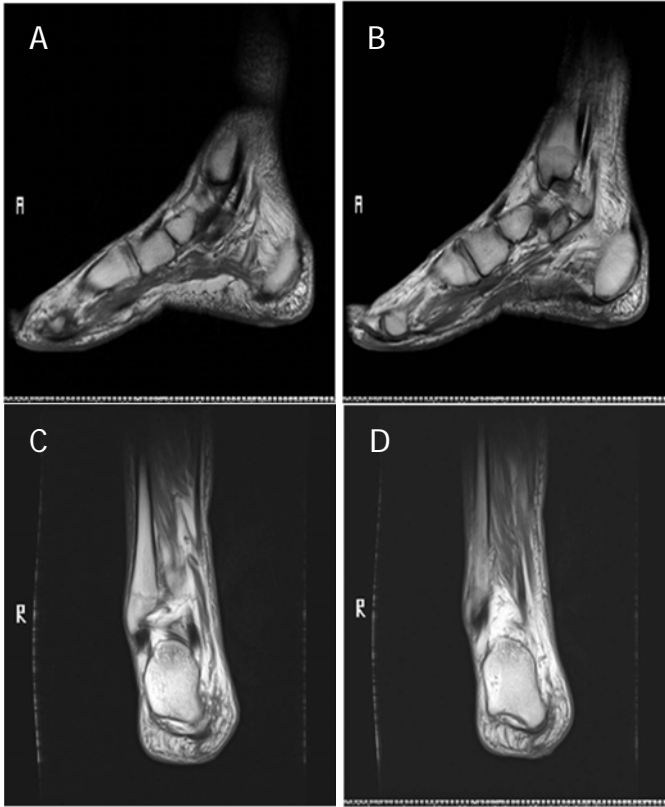In March 2004, an 85 year old African American gentleman presented to the Louis Stokes VAMC emergency department with a complaint of neck, hip, knee, leg and back pain. The patient's past medical history included diabetes, hypertension, and cataract. Additionally, earlier in the month, the patient had been diagnosed with prostate cancer with osteoblastic metastatic disease in the ninth left rib, L<sub>2</sub> and L<sub>5</sub>.

**Address correspondence to:** Donald Kushner, DPM, Dept. of Surgery, Podiatry Division, Louis Stokes Cleveland VA Medical Center, 10107 East Blvd. 112W, Cleveland, OH 44106

<sup>1</sup> Submitted while 3<sup>rd</sup> year resident, Dept. of Surgery, Podiatry Division, Louis Stokes Cleveland VA Medical Center, Cleveland, OH

<sup>2</sup> Submitted while 3<sup>rd</sup> year resident, Dept. of Surgery, Podiatry Division, Louis Stokes Cleveland VA Medical Center, Cleveland, OH

<sup>3</sup> Dept. of Surgery, Podiatry Division, Louis Stokes Cleveland VA Medical Center, Cleveland, OH.



**Figures 1A, 1B, 1C and 1D** MRI of right foot was taken with and without contrast consisting of the following technique. Sagittal STIR, sagittal T1-weighted, coronal T1-weighted, axial PD/T2-weighted, axial T1 fat-sat, and sagittal T1 fat-sat were obtained without contrast. Following gadolinium intravenous administration, sagittal and axial fat-sat T1-weighted images were obtained. (A-D) There is a subtle area of abnormal signal within the skin at the heel of the right foot. It measures 1.2 x 1.1 x 0.4 cm in anterior posterior (AP), transverse, and craniocaudal dimension, respectively. It is slightly hyperintense on both T1 and T2-weighted images compared to the adjacent skin. The skin/dermal layer appears to be displaced deeply by this lesion. There is no extension or connection into the subcutaneous tissue or bony structure seen. (C,D)

Other diagnoses included OA and the patient was given the proper follow-ups with geriatrics, urology and podiatry. In June 2004, he began visits to the LSVAMC podiatry department. The patient presented with a painful lesion on plantar right heel at the site of a puncture wound treated many years prior.

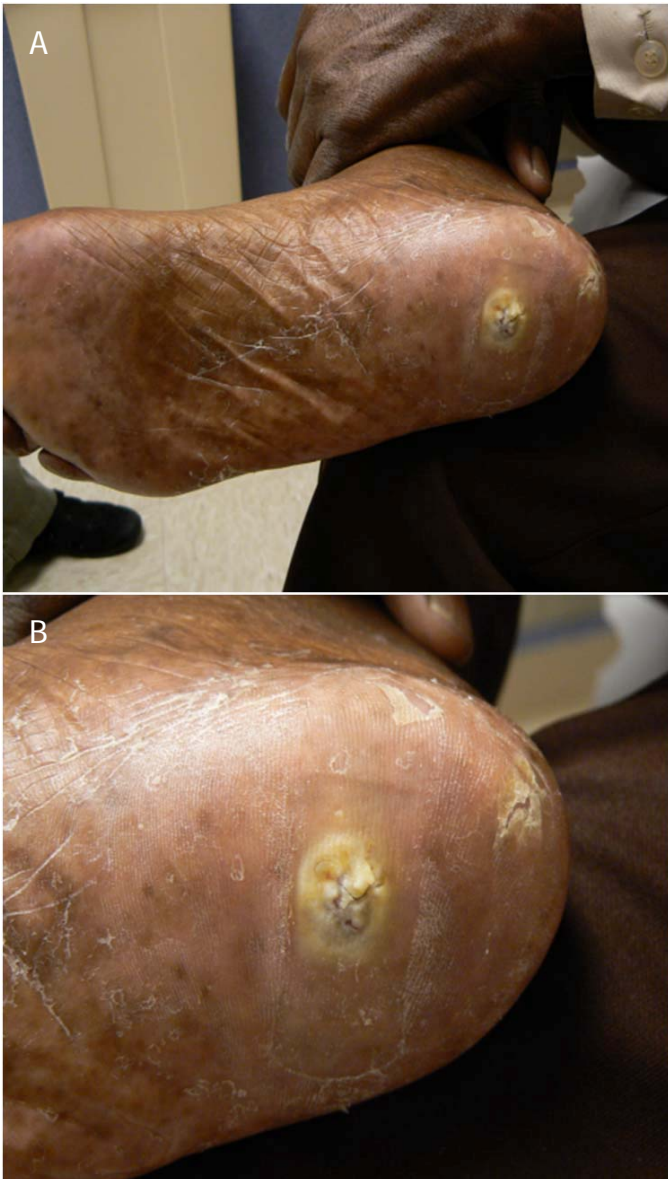The lesion had initially been treated as a plantar wart at a private Cleveland area hospital. This treatment was continued for 5 months until the lesion became ulcerative with deep fissuring. The patient reported that the lesion had been present since 1990, and had varied in appearance throughout this time.

It was felt that this was likely due to frequent debridement as part of the wart treatment. The patient recalled that the lesion had been biopsied in 2003 at a local hospital and was found to be “negative.” Radiographs and magnetic resonance imaging (MRI) were obtained at that time which showed no sign of cortical defect or foreign bodies. MRI revealed a 1cm flat superficial skin lesion under the heel of the right foot without abnormal enhancement. No spread into the subcutaneous tissue, bony involvement or foreign body was seen. (Figs. 1A – D)

By this time surgery had been discussed with patient on several visits and seemed to be established but in December 2004 the patient became unsure of surgery. The patient did not return to clinic until March 2005. The lesion previously measured 0.8 x 0.6cm in July 2004.

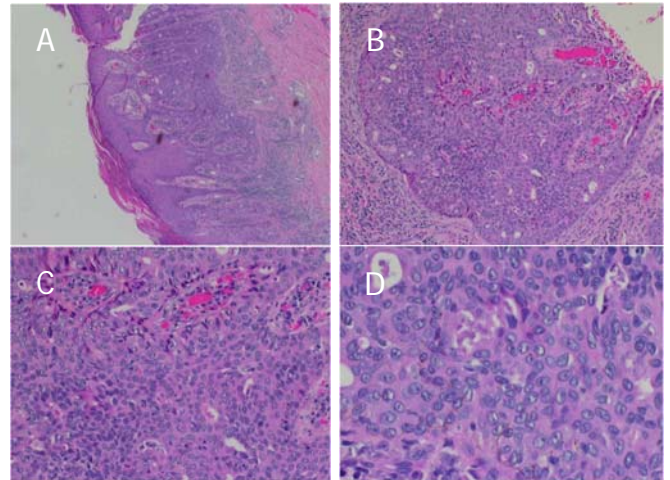
Throughout this time the lesion varied in size and was still fissured, but now with 2 areas of hypergranulation, circumferential maceration and yellowish drainage (Figs. 2A and B). He related that it was common for this lesion to drain occasionally. At this time, the lesion was still present and painful. He related that he had been using Regranex® (Systagenix Wound Management, Johnson & Johnson) for the “ulcer.” He refused biopsy and surgery a second time. For the next 10 months the lesion was treated as a wart or as an ulcer, depending on its appearance at the time of the visit.

During this time the lesion varied in size ranging from 4mm x 5mm to 1.5 cm x 1.0 cm in diameter. In March 2006 the patient returned to clinic stating that he had had the lesion removed by an outside hospital, but the lesion had returned again. The patient was advised about our concern for possible malignancy in this long standing wound. In August 2007, the patient finally agreed to biopsy. A 4mm punch biopsy was performed in podiatry clinic.



**Figures 2A and 2B** Clinical appearance of Intraepidermal eccrine adenocarcinoma exhibiting a hypertrophic lesion at the plantar right heel with deep fissuring and minimal granular tissue seen between fissures. Surrounding skin is macerated with yellowish hue secondary to dressing. (A) A close up view of the lesion is shown. (B)

The biopsy revealed intraepidermal eccrine adenocarcinoma (Fig 3A – D). The dermatology dept at LSVAMC was consulted. Due to the unusual nature of the lesion, the patient was presented at the local University Hospital Multidisciplinary Conference.

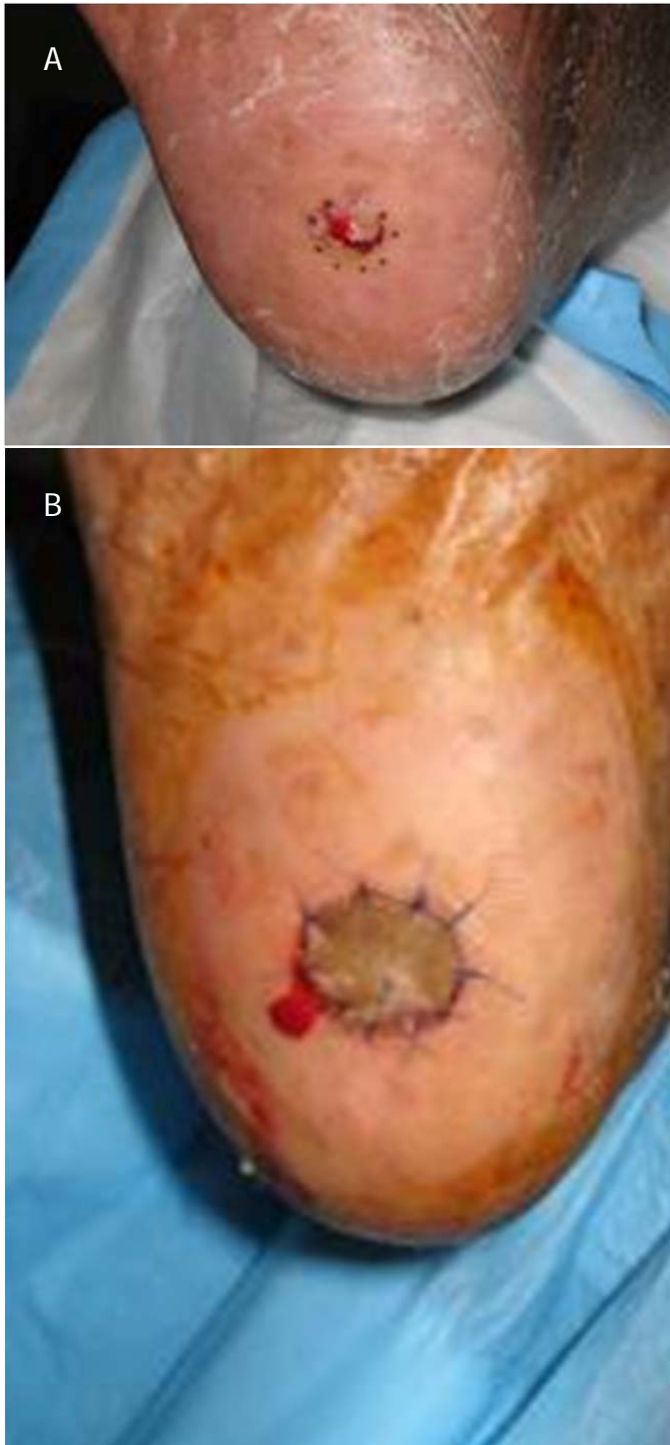


**Figures 3A – D** Histological slide which diagnosed Intraepidermal eccrine adenocarcinoma. Large parakeratotic remnants cap a surface of atypical cells. (A,B) Nodal metastasis, glandular pattern, with atypical nuclei, mitosis, and compressed vascular tissue stroma. (C) Individual tumor cells appearing mildly pleomorphic with cytological atypia. (D)

It was felt that Mohs surgery would be best treatment for the patient, due to the location and pathology of the lesion. Prior to surgery, various studies were performed to ensure that the patient had no existing metastases. No cervical, supraclavicular, axillary, inguinal or popliteal adenopathy was revealed.

In December 2007, the procedure was performed under local anesthesia. Mohs microsurgery was performed utilizing frozen tissue sections and Hemoxyl and Eosin (H&E) stains, as follows: The 1<sup>st</sup> stage of surgery was immediately undertaken by debulking the tumor, and a peripheral and deep margin was excised around the clinically obvious tumor. (Fig. 4A) Hemostasis was established, and a pressure dressing was applied.

The tissue was divided into 2 sections, color coded, and mapped. The sections were then frozen, cut, and stained by the histotechnician. Microscopic examination of the entire tissue margin revealed no residual carcinoma. There was minimal blood loss. All options regarding reconstruction were presented to the patient. Finally, the wound was the reconstructed with graft repair. (Fig.4B)



**Figures 4A and 4B** Initial intraoperative debridement of lesion with scribed mapping of technique to take place. (A) Post operative appearance of lesion with overlying graft which has been sutured into place. (B)

The patient had an initial 2 week follow-up and then once a month. In August 2008 the patient returned for the final appointment. Observation of the right heel revealed a 4mm healed surgical site with mild hyperpigmentation of the graft site. The patient was discharged after this visit. He is now more than 17 months post excision and there has been no recurrence of the lesion. Patient is still seen by the Podiatry department for diabetic foot care and by the Dermatology department for annual evaluation of site.

### Discussion

IEA are rare malignant tumors derived from the eccrine sweat gland. They have been reported in 1 of every 13,000 specimen acquired in pathology laboratory.<sup>8</sup> IEA have tendency to arise in various parts of the body, usually in the trunk and lower extremity, but not uncommonly in the upper extremity, head, neck, or scalp. In a study by Pontone, 46 foot cases with various eccrine cancer types were described. It was found that the most common tumor site for the lower extremity was the sole of the foot.<sup>2</sup> IEA have no distinctive prevalence in sex, age or racial background. Studies vary in regards to sexual predilection, and most will agree that there is no true predisposition to gender.<sup>1,9</sup> Similar to gender, racial background used to be unclear as well. Earlier studies found a higher occurrence in patients of caucasian decent. In 2001, Peterson reported the first case of adnexal carcinoma in an African American.<sup>10</sup>

Since then most research relates no predilection for race. Unlike sex and racial background, studies agree that 50-80 years of age is when most eccrine tumors arise. While it is difficult to determine who is at increased risk of developing IEA, it is thought that immunocompromised patients develop appendageal tumors more frequently than those who are not.<sup>11</sup>

It is thought that IEA and other similar eccrine carcinomas arise from pre-existing benign lesions.<sup>12</sup> As revealed in this case study, IEA are sometimes misdiagnosed due to similarity in appearance to plantar wart, ulcerated polypoid mass or eroded plaques.

If the lesion is inveterate and prior treatment modalities have failed, biopsy of the lesion should take place immediately. In this case report the biopsy was not initially done because the patient had a biopsy a year prior at an outside hospital and it was found negative for malignancy. Foreign body could not be ruled out due to patient history; therefore, x-ray and MRI were obtained. X-ray, although not the gold standard in diagnosing soft tissue/glandular tumors, was useful in this case because it eliminated the diagnosis of metastasis to bone and helped rule out foreign body.

MRI played a similar role, but it also allowed visualization of the depth of the tumor in reference to invasion into dermis and subcutaneous tissue. Some eccrine carcinomas appear as a solid enhancing nodule on MRI although not true in this case. Sweat gland tumors should be considered in the differential diagnosis of a subcutaneous mass regardless of signal characteristics.<sup>13</sup> Biopsy is standard for diagnosis of IEA and similar lesions. A 4mm punch biopsy was taken of the lesion in this case. Biopsy gives a section representation of the lesion and determines if it is benign or malignant in nature. All eccrine tumors have a similar histological appearance. Atypical parakeratotic cells, nodal metastasis in glandular pattern, mitosis, compressed vascular stroma, and pleomorphic tumor cells were evident in determining that the lesion was IEA.

IEA, like other eccrine porocarcinomas, have metastatic potential and can often recur if not treated properly. If metastasis does occur, the prognosis is poor, with mortality rates of 75-80%.<sup>14,15</sup> In this case it was determined that Mohs microsurgery would be the procedure of choice. However, some studies have reported radiation therapy and wide surgical excision as an alternative procedure. In a study by Ryan<sup>5</sup>, 3 cases of malignant eccrine porocarcinomas were identified one of which was treated with radiotherapy. Treatment was uniformly successful in treating the primary skin lesion, but after a year the lesion still managed to cover a significant amount of surface area on the trunk. The management of patients with metastatic malignant eccrine poroma is difficult.

It has proven resistant to many chemotherapeutic agents and radiotherapy has not generally been effective.<sup>16</sup> Pontone's study relates a follow-up for a mean of three years with no recurrence or metastasis. The majority of studies agree that Mohs microsurgery is the treatment of choice.

Mohs microsurgery is a unique microscopic technique that has become the standard of care for removal of certain cutaneous carcinomas. Mohs allows precise marginal control by the use of horizontal frozen sections. It is performed in stages that are determined by the size and depth of the lesion. On average it usually takes 3 stages before no signs of cancer remain. The IEA in the above case was removed by one stage only.

Mohs surgery is performed by dermatologic or oncologic surgeons, and a pathologist. First the external portion of the lesion is debrided. When this layer of skin is removed it is divided into sections. The surgeon color codes each section with dyes and makes reference marks on the skin, hence mapping out the surgical site. Mapping is done prior to injecting with local anesthetic because of possible distortion of the site and anatomic landmarks of the lesion after infiltration. The under surface and the edges of each section are then microscopically examined for evidence of remaining cancer. If cancer is found, its location is then marked and the patient will have to return to the minor procedure room to remove another layer of skin, but now it is more precise to where the cancer remains. The process will continue until no evidence of cancer remains.

Another benefit of Mohs microsurgery is that it only removes tissue consisting of cancer cells; therefore the maximum amount of healthy tissue remains intact. Mohs is cost effective in comparison to radiation therapy or wide surgical excision in the operating room. At the completion of the procedure, the resulting defect is immediately reconstructed. A graft is usually placed on the site and sutured into place (Fig 4B), or it is allowed to heal via secondary intention.

Mohs, like any surgery, does have complications which can be considered as minor. These include post operative hematoma, seroma, wound dehiscence, flap necrosis, graft failure, infection, contact dermatitis to antibiotic ointments or dressing materials, excessive granulation formation, keloid and/or hypertrophic scar formation, hyperpigmentation and/or hypopigmentation, and recurrence of the tumor.<sup>17</sup> The possibility that a lesion will recur cannot be ruled out, but Mohs microsurgery has been proven to have a much lower rate of recurrence than any of other surgical treatments. Since eccrine tumors can be considered as rare, a comparative treatment study has not been created.

In conclusion, IEA are rare and those in the lower extremity are most often found on the sole of the foot. They should not be excluded as a differential diagnosis with lesions such as plantar warts, hypertrophic/hypergranular ulcer or polypoid mass is noted on the skin, especially, if present for long periods with no improvement. The standard for diagnosis is biopsy. Once the pathologist relates intraepidermal adenocarcinoma as a diagnosis immediate consultation to the dermatologist is recommended. The majority of IEA are associated with local aggressive metastasis. Therefore, Mohs microsurgery is now mandated, due to higher frequency of recurrence with surgical excision. Patients should also be advised that long-term follow-up care is needed.

## References

1. Kauderer C, Clarke HD, Fatone CT. Malignant eccrine acrospiroma: A case study. *J Am Podiatr Med Assoc* 85: 116 – 117, 1995.
2. Pontone M, Potter GK, Berlin S J, Reiss PA, Levin RS, Mantell GM, Gleitman D, Kennelty JM, Simon SD, Kahn JB, Havens RT, Semer LC. Malignant eccrine neoplasms of the Foot. *J Foot Ankle Surg* 33: 486 – 491, 1994.
3. Cowden A, Dans M, Militello G, Junkins-Hopkins J, VanVoorhees A S. Eccrine porocarcinoma arising in two African American patients: distinct presentations both treated with Mohs micrographic surgery. *International J Dermatol* 45: 146 – 150, 2006.
4. Pinkus H, Rogin JR, Goldman P. Eccrine poroma: tumour exhibiting features of the epidermal sweat duct unit. *Arch Dermatol* 174: 511 – 521, 1956.
5. Ryan JF, Darley CR, Pollock DJ. Malignant eccrine poroma: report of three cases. *J Clin Pathol* 39:1009-1104, 1986.
6. Huet P, Dandurand M, Pignodel C, Guillot B. Metastasizing eccrine porocarcinoma: report of a case and review of the literature. *J Am Acad Dermatol* 35: 860 – 864, 1996.
7. Dzubow LM, Grossman DJ, Johnson B. Chemosurgical Report: Eccrine Adenocarcinoma-Report of a Case, Treatment with Mohs Surgery. *J Dermatol Surg Oncol* 12: 1049 – 1053, 1986.
8. Mehregan AH, Hasimoto K, Homayoon R. Eccrine adenocarcinoma- a clinicopathologic study of 35 cases. *Arch Dermatol* 119: 104 – 114, 1983.
9. Emanuele Ferri, Gaetano Antonio Iaderosa, Ernico Armato. Metastasizing eccrine porocarcinoma of the nose: case-report with immunohistochemical study and review Of the literature. *The Internet Journal of Otorhinolaryngology*. 7 2: 2008.
10. Peterson CM, Ratz JL, Sanguenza OP. Microcytic Adnexal Carcinoma: First reported case in an African American man. *J Am Acad Dermatol* 45(2):283 – 285, 2001.
11. Harwood CA, McGregor JM, Swale VJ, Proby CM, Leigh IM, Newton R. High frequency and diversity of cutaneous appendageal tumors in organ transplant recipients. *J Am Acad Dermatol* 48: 401 – 408, 2003.
12. Shaw M, McKee PH, Lowe D, Black MM.. Malignant eccrine poroma - a study of 27 cases. *Br J Dermatol* 107: 675 – 680, 1982.
13. Allan R, Reier AR, Ashman CJ, Miles L. MR imaging appearance of plantar eccrine acrospiroma (Sweat gland tumor). *Am J Roentgeno* 179:1079-80, 2002.
14. Harvell JD, Keroehmann RL, LeBoit PE. Eccrine or apocrine poroma? Six poromas with divergent adnexal differentiation. *Am J Dermatopath* 18: 1 – 9, 1996.
15. Affleck AG, Bong JL, Ostrounova MA, Leach IH, Perks AG, Varma S. Eccrine porocarcinoma. *Dermato Online J* 12(1):17.
16. Harari PM, Shimm DS, Bangert JL, Cassady, JR. The role of radiotherapy in the treatment of malignant sweat gland neoplasms. *Cancer* 65:1737 – 1741, 1990.
17. Mooney, M., Parry, E. Mohs Micrographic Surgery. *EMedicine by web MD*; updated Feb 21, 2007.