

## Navicular dislocation and orthotic management: A case study

by Joshua Young BSc.(Hons), MBAPO Orthotist<sup>1\*</sup>

The Foot and Ankle Online Journal 11 (3): 2

Navicular dislocation is a rare injury, typically managed by surgical fixation. This case study presents the results of conservative management of navicular dislocation, using a custom foot orthosis, combined with a removable walker boot. At 6 week review the numeric pain rating scale (NRS-11) score was reduced from 8/10 to 3/10. A foot orthosis combined with a removable walker boot may reduce pain in the short term in non-operable navicular dislocation more successfully than a walker boot alone.

**Keywords:** navicular, navicular dislocation, orthoses, orthotics

This is an Open Access article distributed under the terms of the Creative Commons Attribution License. It permits unrestricted use, distribution, and reproduction in any medium, provided the original work is properly cited. ©The Foot and Ankle Online Journal ([www.faoj.org](http://www.faoj.org)), 2018. All rights reserved.

**D**islocation of the navicular without fracture is a rare injury [1-3]. A 2015 case study by Singh and colleagues found 16 previously reported cases in the literature [2]. A further case study was published in 2016 [1]. Two other published cases were not identified which gives a total estimate of 20 published cases in the literature to date [4,5].

The mechanics of injury are commonly described as involving pronation, with abduction of the forefoot [6]. Davis and colleagues describe a transient midtarsal dislocation which allows the navicular to dislocate [3]. The navicular may displace in a plantar or dorsal direction, depending on the nature of the injury. Dhillon and Nagi argue that the injury is never truly an isolated injury as disruption to both the medial and lateral columns of the foot is necessary [6].

Surgical management is usually recommended, typically with temporary Kirschner wire fixation, although other means of fixation may be used [1-3]. Custom foot orthoses have been suggested as a possible treatment option for surgically corrected

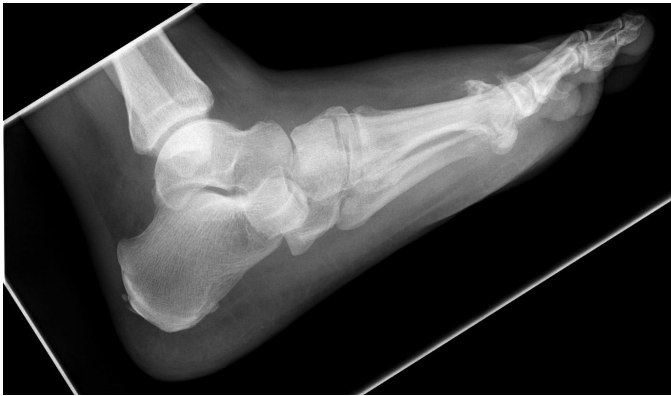cases of navicular dislocation which remain painful however there are no reported cases of purely conservative management of navicular dislocation of which the author is aware [1]. This case report presents a navicular dislocation managed purely conservatively using orthoses due to surgical risk factors which made the subject a poor candidate for surgery.

### Case report

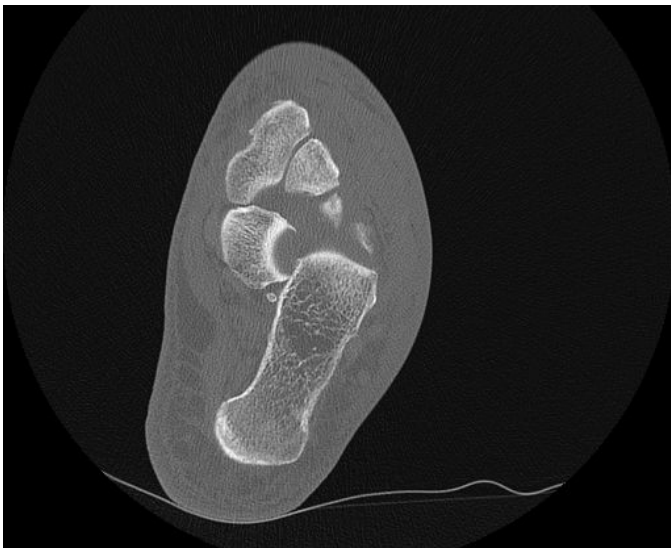A 67-year-old male was referred to see an orthotist in the orthotic service by his orthopedic foot and ankle consultant. The subject had an injury to his left foot 5 months previously sustained during a fall which occurred whilst walking indoors. Initial radiographs and computed tomography scans following the fall show a dislocated navicular and cuboid fracture (Figures 1-4). One month post injury radiographs showed reduced 11 degree calcaneal inclination angle on the left (affected) side compared to 24 degrees on the right, reflecting a reduction in height of the medial longitudinal arch.

1 - Roehampton Rehabilitation Centre, Queen Mary's Hospital. St George's University Hospitals NHS Foundation Trust; Opcare, Oxfordshire, UK.

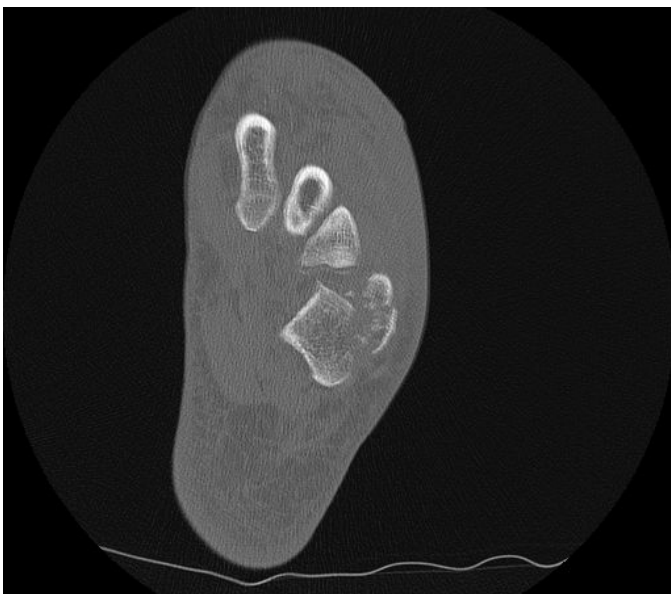\* - Corresponding author: [Joshua.Young@stgeorges.nhs.uk](mailto:Joshua.Young@stgeorges.nhs.uk)



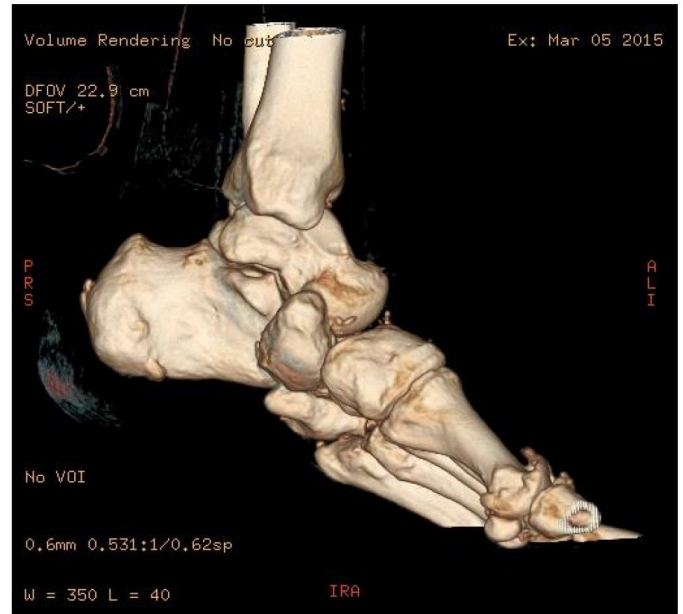
**Figure 1** Dislocated navicular resting inferior to the sustentaculum tali.



**Figure 2** Dislocated navicular resting inferior to the sustentaculum tali.



**Figure 3** Cuboid fracture.



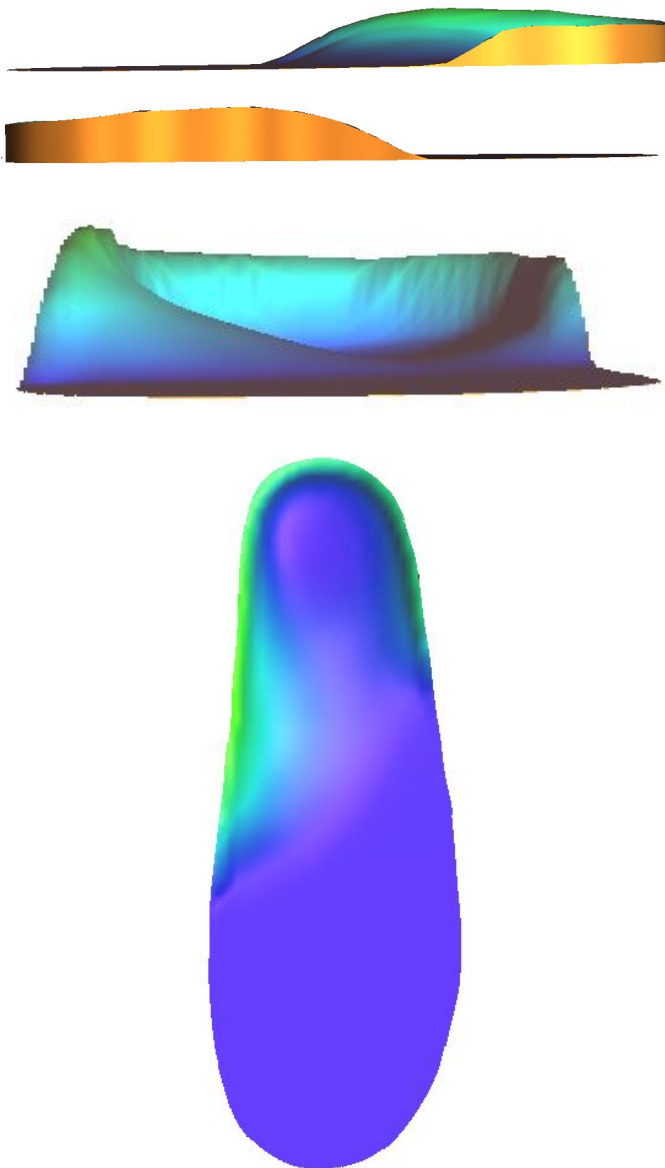
**Figure 4** Three dimensional CT reconstruction showing dislocated navicular.

A significant factor in the injury was the subject's body weight which at 2 months following the injury was 161kg (Body Mass Index 50). At the time of assessment in orthotic clinic 3 months later, this had increased to 189kg (Body Mass Index 56). The increased body weight will have increased the ground reaction forces experienced by the foot, and the resultant internal stresses on tissues such as ligamentous tissue which normally help to maintain joint congruency [7,8].

Following two orthopedic opinions, and assessment in a high risk anesthetic clinic, it was agreed to avoid surgery due to the high risk of mortality. It was observed that the talar head was now articulating with the medial cuneiform, forming a pseudo joint.

At presentation in orthotic clinic the subject reported pain as the primary concern. His walking was very limited to short distances indoors, wearing a removable walker boot (Aircast Airselect, Donjoy). He reported pain at an intensity of up to 8 out of 10 (numeric rating scale, NRS-11). A custom ankle foot orthosis (AFO) was considered to limit painful movement within the foot, however this was decided to not be feasible as the subject would struggle to apply or remove this independently [9]. A custom foot orthosis (FO) was prescribed to wear inside the walker boot. The mechanical aim of this was to apply forces to the medial longitudinal arch in an attempt to

modify compressive stresses assumed to be occurring at the midfoot and talo-cuneiform pseudo-joint, and tensile stresses assumed to be occurring in soft tissues at the plantar foot [9]. The FO was made from an imprint of the foot in a foam impression box using a computer aided design and manufacture (CAD-CAM) system (Paromed, Neubeuern, Germany). The FO was manufactured using 70 shore material at the heel to midfoot, and softer 50 shore material from the midfoot to the forefoot. A soft 3.2mm grey poron polyurethane foam cover (Algeos, Liverpool, UK) was added. The shape of the FO is demonstrated by the modeling images (Figure 5a-d).



**Figure 5** Custom foot orthosis, medial view (a), lateral view (b), anterior view (c), dorsoplantar view (d).

At 6 week review the subject reported good compliance with wearing the FO within the walker boot. Using the 11 point numeric pain rating scale (NRS-11), pain intensity during walking was reported to be reduced from 8/10 to 3/10.

## Discussion

This case study presents the results of conservative management of an unusual foot injury. A custom FO, combined with a walker boot, reduced pain intensity in the short term. Pain was still present while using the walker boot only. The reported reduction in pain following addition of the FO may imply that the FO was able to modify stresses in the midfoot, even in the presence of very high body weight, in order to be effective. FOs are rarely used for this specific application due to the rarity of the injury, however they may be combined with walker boots to manage Charcot foot which is also associated with major change of the midfoot architecture. Limitations of this study include a lack of further outcome measures, and possible bias incurred by the treating clinician administering the NRS-11 pain scale. This case study illustrates the possibility that even major changes in the bony structure of the foot, which are symptomatic, may be manageable to some extent conservatively using foot orthoses.

## Acknowledgements

The author would like to acknowledge Dominic Nielsen, consultant orthopaedic surgeon, for his comments on the paper.

## References

1. Ansari MAQ. Isolated complete dislocation of the tarsal navicular without fracture: A rare injury. *Ci Ji Yi Xue Za Zhi*. 2016;28(3):128-131.
2. Singh VK, Kashyap A, Vargaonkar G, Kumar R. An isolated dorso-medial dislocation of navicular bone: A case report. *J Clin Orthop Trauma*. 2015;6(1):36-8.
3. Davis AT, Dann A, Kuldjanov D. Complete medial dislocation of the tarsal navicular without fracture: report of a rare injury. *J Foot Ankle Surg*. 2013;52(3):393-6.
4. Hamdi K, Hazem BG, Yadh Z, Faouzi A. Isolated dorsal dislocation of the tarsal naviculum. *Indian J Orthop*. 2015;49(6):676-9.
5. Dias MB, Zagonel B, Dickel MS, Talheimer JA, Argenton IS, et al. Isolated dislocation of the tarsal navicular without fracture: Case report. *Trauma Cases*. 2016,Rev 2:045

6. Dhillon MS, Nagi ON. Total dislocations of the navicular: are they ever isolated injuries?. *J Bone Joint Surg Br.* 1999;81(5):881-5.
7. Browning RC, Kram R. Effects of obesity on the biomechanics of walking at different speeds. *Med Sci Sports Exerc.* 2007;39(9):1632-41.
8. Pamukoff DN, Lewek MD, Blackburn JT. Greater vertical loading rate in obese compared to normal weight young adults. *Clin Biomech (Bristol, Avon).* 2016;33:61-65.
9. International standards organization. *ISO 8549-3, Prosthetics and orthotics - Vocabulary - Part 3: Terms relating to external orthoses.* 1989.